



# A Case of Severe Adenomyosis in a Young Adolescent

**Ahmed Abdulwahab Abdulkarim**

Obstetric and Gynecology Department, King Saud University, King Saud Medical City, Riyadh, KSA

**Email address:**

Awkarim55@yahoo.com

**To cite this article:**

Ahmed Abdulwahab Abdulkarim. A Case of Severe Adenomyosis in a Young Adolescent. *Science Journal of Clinical Medicine*.

Vol. 10, No. 4, 2021, pp. 85-88. doi: 10.11648/j.sjcm.20211004.11

**Received:** June 16, 2021; **Accepted:** July 8, 2021; **Published:** October 30, 2021

---

**Abstract:** Adenomyosis refers to a disorder in which endometrial glands are present within the uterine muscle which can be either diffuse or localized that may cause heavy menstrual bleeding, dysmenorrhea, and infertility. The disease usually affects multiparous women. Around 70-80% of the cases are reported in women of age between 40 and 50 years. Very few cases of adenomyosis in young adolescent are reported, and the diagnosis in such case becomes notoriously difficult, but still can be highly suspected with the help of ultrasound (USS) and Magnetic Resonance Imaging (MRI). Here, we present a case of 15-year old girl attending the emergency care with acute abdominal pain. The patient underwent diagnostic laparoscopy which revealed bleeding in the peritoneal cavity and a big hypertrophied uterus. Erosion and active bleeding was observed from the surface of the uterus; the case was advanced to laparotomy. The uterus was uniformly enlarged and boggy that was completely eroded and bled actively. Multiple biopsies were taken from different parts of uterine lesion and sent for frozen section histopathology examination. The blood was sucked from the peritoneal cavity, followed by placement of multiple hemostatic stitches. The results revealed severe adenomyosis. Only very few cases of adenomyosis in adolescents are reported to date and since fertility preservation is considered as an important goal, the traditional treatment of endometriosis may not be applicable to treat adenomyosis in case of young adolescent for fear of jeopardizing the reproductive life. Preserving the fertility in the adolescent and young adult patients poses a major challenge keeping in mind the adequate treatment required without affecting the general health of the patient.

**Keywords:** Adolescent, Adenomyosis, Adenomyoma, Fertility Preservation

---

## 1. Introduction

Adenomyosis is a benign condition of the uterus characterized by the presence of endometrial glands and stroma in the uterine myometrium and it is not uncommon in women in their late reproductive life, and has been found that 5-7% of hysterectomy fibroid uteri and often associated with diffuse subtype.

However in adolescent girls the incidence is not known, since few cases has been reported.

Although adenomyosis seems very rare before the age of 20, cystic form has mainly been reported in young women [1, 2].

Since the fertility in young adolescent should be taken in consideration every effort should be done in order to conserve the uterus and hence the medical treatment plays a pivotal rule in the management of adenomyosis in young adolescent of hysterectomy.

## 2. Case Report

A 15-year old girl presented with a history of abdominal pain of 2 days' duration. The pain initially commenced in the lower abdomen and later spread across entire abdominal area that was associated with nausea, vomiting and fever. The patient gave a history of irregular menstrual cycles since menarche with extreme menstrual bleeding. The hemoglobin level had dropped to 6 g/l but her response to oral iron supplementation and oral progestin was good.

The patient had a history of laparoscopy performed two years ago at the aged of 13 years and was found to have adhesion between the right ovary and fallopian tube. The uterus was bulky, enlarged and globular in shape, and there was focal nodular eruption on the surface of the entire uterus. Bacteriological and cytological studies were both negative and no definitive diagnosis was made at that stage.

The patient was treated conservatively and she responded well to analgesic drugs.

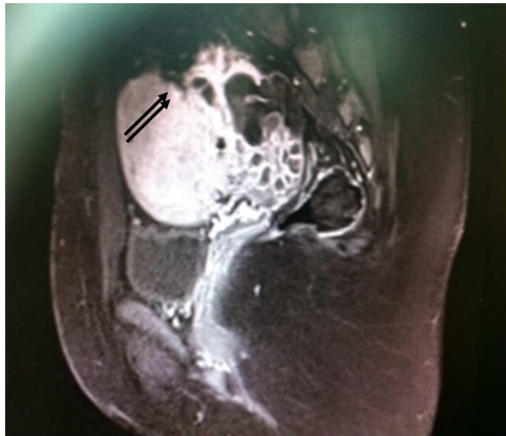
### 3. General Examination

The blood pressure recording was 100/65 mmHg, pulse measurement showed 110 beats per minute and temperature was 37.8°C.

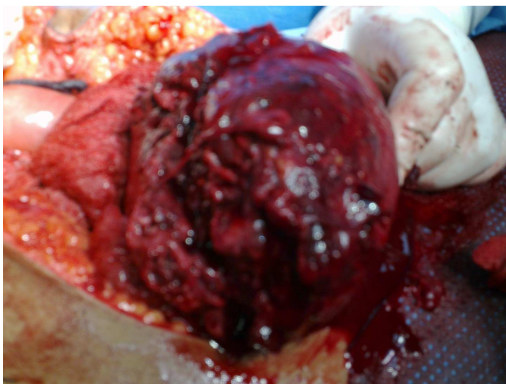#### *Abdominal examination:*

The abdomen was tense, tender, distended and rigid. There were no obvious palpable masses. A previous USS done two years back showed irrelevant small anterior wall fibroid measuring 2.3X1.9 cm and another one in the posterior wall with dimensions 2.9X2.3 cm. However, USS performed during admission showed a large non-homogenous mass which could represent an enlarged uterus with free fluid in the pouch of Douglas.

CT scan demonstrated a large complex heterogeneous predominantly hypoechoic mass with enhancing thin septa occupying the uterine fundus and right adnexa with involvement of both myometrium and endometrium that measured 12.5X10.5X15 cm, with moderate amount of free fluid in the abdomen and pelvis. (Figure 1)



**Figure 1.** CT scan showing a large hypertrophied uterus with eroded surface (arrow) and free fluid in the pelvis.



**Figure 2.** Diffuse adenomyosis involving the fundus of the uterus and eroding the surface causing bleeding.

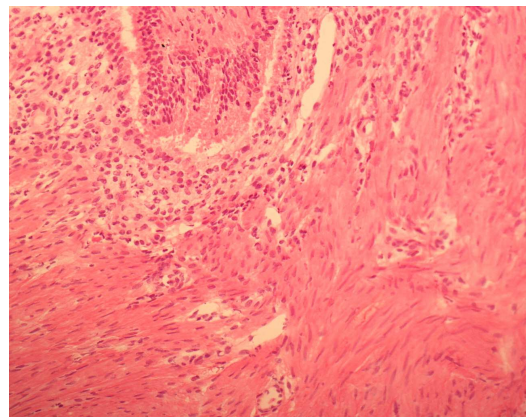
The laboratory investigations were normal except for the tumor markers CA-125 which was 3478 IU/L.

Exploratory laparotomy was performed and the patient was found to have moderate amount of free blood in the abdominal cavity, and the uterus was enlarged with a fungating mass mainly at the fundus and to a lesser extent, towards the anterior aspect of the uterus (Figure 2), while there was active bleeding encountered from the eroded uterine surface. There was also a dense adhesion to the large bowel. Frozen section was taken for histopathology since the gross picture showed likelihood of feature of sarcoma. But the histopathology reports declared negative for malignancy.

Multiple hemostatic stitches were taken and the raw area was covered with anti-adhesion barrier. All of these procedures were carried-out as in-patient procedures during hospitalization and the sutures were removed on the 8<sup>th</sup> day. However, due to gaping of wound after the removal of the stitches, it was resutured under local infiltrative analgesia.

On the 10<sup>th</sup> day the patient developed shortness of breath and was diagnosed to have developed pulmonary embolism. She was initially put on heparin and continued further with low molecular weight heparin and later on with warfarin. The patient stayed in hospital for three weeks and was discharged after removal of the external sutures.

The patient was prescribed GnRH agonist once a month for six months and a repeat ultrasound showed a mildly enlarged uterus. The CA-125 had significantly dropped to 343.30 IU/L. Histopathology confirmed severe adenomyosis (Figure 3).



**Figure 3.** Showing severe adenomyosis with endometrial glands within the myometrium.

### 4. Discussion

Adenomyosis is a benign condition characterized by the presence of ectopic endometrial glands within the uterine myometrium, and this may be present in diffuse or focal forms such as adenomyomas. Although reports of adenomyosis are common among adults, few cases have been shown to occur in adolescents [1-3]. The pathogenesis of adenomyosis is not well understood [1] but some studies suggest that both endometriosis and adenomyosis occur as a result of trauma either mechanical or due to spread of the ectopic glands in the vascular channels. Angiogenesis also has been involved. There is an increasing evidence that

supports a genetic component to this common gynaecological condition. Recent molecular cytogenetic studies on endometriotic tissue and an established endometriosis-derived cell line provide novel evidence that acquired chromosome-specific alterations may be involved in endometriosis genetic linkage. Finally many inflammatory factors such as tumor necrosis factors, prostaglandins, and interleukins have been implicated in the pathogenesis of the endometriotic lesions.

The presenting symptoms in adolescent are ranging from abnormal uterine bleeding, chronic pelvic pain, to nonspecific genitourinary or gastrointestinal complaints (4). However studies addressing adenomyosis or adenomyoma in the adolescents report severe dysmenorrhea that is unresponsive to non-steroidal anti-inflammatory drugs (NSAID) or combined oral contraceptive pills, as the most common complaint [5-11]. Very few case reports have so far addressed adenomyosis in female adolescent. In all cases of adenomyoma, traditional therapies were found to be symptom refractory, ultimately requiring surgical excision [5, 4, 9-11]. Traditionally the diagnosis of adenomyosis is made with the histopathology following hysterectomy in adult, but in the present case, being a 15-year old girl, multiple biopsies were taken to rule out sarcoma. The histopathological diagnosis of severe adenomyosis (Figure 3) was well supported by the clinical presentation of the menorrhagia with the uniformly enlarged uterus seen in the CT scan.

With regard to marked increase in CA125 levels, it is well known that normally, CA125 is derived from the normal epithelia of the endometrium, making it possible to diagnose adenomyosis at earlier stage [12] This can be considered as a noninvasive diagnostic tool for early diagnosis without subjecting the young adult to the risk of surgery and its subsequent complications, especially her fertility status. In addition, early intervention through appropriate management helps in disease regression and improving the quality of the patients life.

For the treatment of adenomyosis in adolescent, both medical and surgical management offer a good chance for disease stabilization and regression. Initial therapy for focal adenomyosis involves hormonal suppression with combined oral contraceptive pills, and this is particularly important for the female adolescent in whom preserving the fertility is of paramount importance.

In rare cases where focal lesions (adenomyoma) do not respond to medical treatment, surgical excision of the lesions is recommended for the lesions located in the myometrium sparing the uterine cavity.

In case of older women with diffuse adenomyosis and whose symptoms are refractory to medical management, definitive surgical intervention may be recommended since fertility is not a major concern. Although surgical intervention may be an optimal mode of treatment for chronic pelvic pain, studies have reported no differences in recurrence rates between ablation and excision of the lesions [8].

With a focus on fertility preservation, the traditional medical treatment of endometriosis has been tried to treat

adenomyosis since the mechanism of the disease is the same. [13] Suppression of ovulation using oral contraceptive pills, medroxyprogesterone and depoleuprolide acetate is a well-known treatment modality for endometriosis and has been tried similarly for treatment of adenomyosis, however its long term effectiveness has not been evaluated [5]. There is a recent study confirming that adolescent and young women respond better to medical and surgical treatment to prevent endometriosis progression. Medical treatment include combined hormonal contraceptives pills, high dose progesterone danazole, gestrinone and GnRH agonists [14]. Because of the interest of fertility preservation in adolescence, most of the treatment modalities are pooled towards medical management which theoretically has less adverse effects on fertility than surgery.

Aromatase inhibitors, (anastrozole, letrozole) inhibit mainly extra-ovarian synthesis of oestrogens. Therefore, the use of aromatase inhibitors seems to be particularly relevant in older patients, as most of the body's oestrogen is produced outside the ovaries after menopause and its role in the management of adenomyosis in young adolescent is not yet confirmed however further research is needed to determine long term effectiveness [15].

Recent studies have reported the use of hormonal intrauterine device (LNG-IUD) to be effective in the management of adenomyosis by relieving the dysmenorrhea and reducing the uterine volume in older patients, however its use in adolescents must be exercised with great caution [16].

## 5. Conclusion

Adenomyosis is common in women of child bearing age and is rarely encountered in young adolescent especially in the severe form, in which mainly the patients represents with severe dysmenorrhea. In our case this young adolescent presented with acute surgical abdomen and hemoperitonium which considered a rare presentation causing a dilemma in the diagnosis which in this case the diagnosis was made by histopathology frozen section. Management of such a life threatening condition is very challenging since the primary goal in her case is to salvage her life and the second goal is to preserve her fertility and a pivotal additional medical treatment should be taken into in the balance of the pros and cons of fertility preservation.

## Disclosure

The author declare no potential conflicts of interest and no source of support.

## References

- [1] Naftalin J, Hoo H, N, Holland T, Mavrellos D, et al (2016) Association between ultrasound features of adenomyosis and severity on menstrual pain *Ultrasound Obstet Gynecol* 47; 779-783.

- [2] Tsui KH, Lee WL, Chen CY, Sheu BC, Yen MS, et al (2014) Medical treatment for adenomyosis and/or adenomyoma. *Taiwan j Obstet Gynecol* 53; 459-465.
- [3] Senturk LM, Imamoglu M. Adenomyosis: what is new? *Womens Health (Lond)*. 2015 Aug; 11 (5): 717-24.
- [4] Singh S, Best C, Dunn S, Leyland N, Wolfman WL. Society of Obstetricians and Gynaecologists of Canada (SOGC) No. 292-Abnormal Uterine Bleeding in Pre-Menopausal Women. *J Obstet Gynaecol Can*. 2018 May; 40 (5): e391-e415.
- [5] Wouk N, Helton M. Abnormal Uterine Bleeding in Premenopausal Women. *Am FamPhysician*. 2019 Apr 1; 99 (7): 435-443. PubMed PMID: 30932448.
- [6] Vidal IS, Soares LS, Dutra CA, Jovino MJ, Gonçalves AK, et al. (2018) Adenomyosis in an 18-Year-Old Adolescent: A Case Report. *Obstet Gynecol Cases Rev* 5: 121. doi.org/10.23937/2377-9004/1410121.
- [7] AboubakrElnashar. Emerging treatment of endometriosis. *Middle East Fertility Society*. 2015 June 20 (2): 61-69.
- [8] Koukoura O, Kapsalaki E, Daponte A, Pistofidis G. Laparoscopic treatment of a large uterine cystic adenomyosis in a young patient. *BMJ Case Rep*. 2015 Oct; 2015. pii: bcr2015210358. doi: 10.1136/bcr-2015-210358. PubMed PMID: 26430229; PubMed Central PMCID: PMC4600803.
- [9] Cucinella G, Billone V, Pitruzzella I, Lo Monte AI, Palumbo VD, Perino A. Adenomyotic cyst in a 25-year-old woman: case report. *J Minim Invasive Gynecol*. 2013 Nov-Dec; 20 (6): 894-8. doi: 10.1016/j.jmig.2013.04.022. Epub 2013 Jul 10. PubMed PMID: 23849619.
- [10] Chun SS, Hong DG, Seong WJ, Choi MH, Lee TH. Juvenile cystic adenomyoma in a 19-year-old woman: a case report with a proposal for new diagnostic criteria. *JLaparosc Adv Surg Tech A*. 2011 Oct; 21 (8): 771-4. doi: 10.1089/lap.2011.0014.Epub 2011 May 11. PubMed PMID: 21561337.
- [11] Howard FM. Surgical treatment of endometriosis. *Obstet Gynecol Clin North Am*. 2011 Dec; 38 (4): 677-86. doi: 10.1016/j.ogc.2011.09.004. Review. PubMed PMID: 22134016.
- [12] Oliveira MAP, Raymundo TS, Soares LC, Pereira TRD, Demôro AVE. How to Use CA-125 More Effectively in the Diagnosis of Deep Endometriosis. *Biomed Res Int*. 2017; 2017: 9857196. doi: 10.1155/2017/9857196. Epub 2017 Jun 4. PubMed PMID: 28660213; PubMed Central PMCID: PMC5474266.
- [13] Harmsen MJ, Wong CFC, Mijatovic V, Griffioen AW, Groenman F, Hehenkamp WJK, Huirne JAF. Role of angiogenesis in adenomyosis-associated abnormal uterine bleeding and subfertility: a systematic review. *Hum Reprod Update*. 2019 Sep 11; 25 (5): 647-671. doi: 10.1093/humupd/dmz024. PubMed PMID: 31504506; PubMed Central PMCID: PMC6737562.
- [14] Słopeń R, Męczekalski B. Aromatase inhibitors in the treatment of endometriosis. *Prz Menopauzalny*. 2016 Mar; 15 (1): 43-7. doi: 10.5114/pm.2016.58773. Epub 2016 Mar 29. Review. PubMed PMID: 27095958; PubMed Central PMCID: PMC4828508.
- [15] Kelekci S, Kelekci KH, Yilmaz B. Effects of levonorgestrel-releasing intrauterine system and T380A intrauterine copper device on dysmenorrhea and days of bleeding in women with and without adenomyosis. *Contraception*. 2012 Nov; 86 (5): 458-63. doi: 10.1016/j.contraception.2012.04.001. Epub 2012 Jul 24. PubMed PMID: 22832203.